

PATIENT

Kahlen Topper

PRESENTING CLINICAL SIGNS

History: Possible collapse episode. H/o pheochromocytoma.
Pertinent abnormal lab results (EL 4/14/22): Normal

SPECIES

Canine

BREED

Bulldog Mix

SEX

Male Neutered

AGE

12 years

WEIGHT

74 lbs

INTERPRETED BY

Maggie Machen Lamy,
DVM, DACVIM
(Cardiology)

IMAGING PERFORMED BY

HOLTER MONITOR FINDINGS AND RHYTHM ASSESSMENT

Time analyzed	23:53h
Mean heart rate	74bpm
Maximum heart rate	183bpm
Minimum heart rate	40bpm
VPCs	3; 1 couplet
APCs	0

Interpretation: Underlying normal sinus rhythm with appropriate rate variation. Infrequent single VPCs; monomorphic with a single couplet (inst HR 166bpm). During presumed sleep, occasional pauses noted with a ventricular escape foci firint.

Rhythm diagnosis: Sinus rhythm with rare single VPCs and a single couplet.

INTERPRETATION OF THE FINDINGS & FURTHER RECOMMENDATIONS

The monitor documents primarily a normal sinus rhythm. Rare single VPCs are noted, which are not surprising in an older large breed dog. While a couplet is somewhat concerning, the coupling interval is reasonable, and overall markers of malignancy are low. There is no clear indication that these are related to the collapse episode. That being said, any animal with VPCs has the risk for sustained arrhythmias such as VT/VF and potential for sudden death.

In the absence of markers of malignancy (polymorphism, R on T, triplets, etc), no clear indication for anti-arrhythmic therapy at this time. Recommend close monitoring at home; however, as if persistent episodes are noted this may be revisited. Consider educating the owner on obtaining a heart rate during any future episodes to help determine correlation with rapid arrhythmias (palpation, auscultation, AliveCor monitor). Activity restriction is advised.

Fish oil supplementation is recommended for dogs with arrhythmias (1000mg of omega 3/6 once to twice daily).

HOSPITAL NAME

Rockaway AH

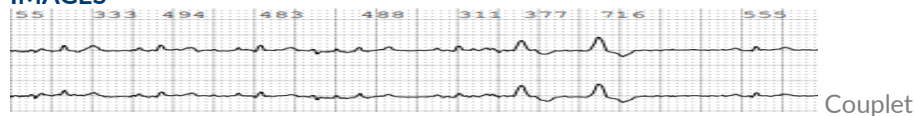
Monitor at home for further collapse, exercise intolerance, and/or lethargy. Consider an AliveCor monitor for at home HR/ECG monitoring.

A recheck ECG and/or holter monitor is recommended in 6 months, sooner if further episodes of collapse occur.

REFERRING VET

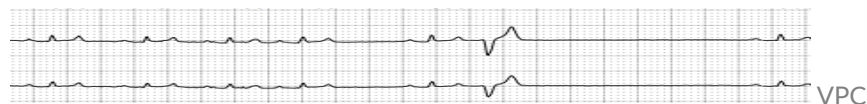
Dr. Maniar

IMAGES



INVOICE

23935



DATE

4/28/22



PATIENT

Kahlen Topper

The information and recommendations provided are based on the images presented by the referring veterinarian. No evaluation can be communicated regarding pathology that was not visible in the image/video clips provided.

SPECIES

Canine

Thank you for this referral. If the clinical or image interpretation does not parallel your findings or if I can be of any further assistance please contact me.

BREED

Bulldog Mix

Maggie Machen Lamy, DVM
Diplomate of the American College of Veterinary Internal Medicine (Cardiology)
info@sonopath.com

SEX

Male Neutered

AGE

12 years

WEIGHT

74 lbs

INTERPRETED BY

Maggie Machen Lamy,
DVM, DACVIM
(Cardiology)

**IMAGING
PERFORMED BY**

HOSPITAL NAME

Rockaway AH

REFERRING VET

Dr. Maniar

INVOICE

23935

DATE

4/28/22